

## EFFICACY OF PREOPERATIVE MRI IN DETECTING BICEPS TENDON PATHOLOGIES IN ROTATOR CUFF TEARS: CORRELATION OF MRI AND INTRAOPERATIVE FINDINGS

### ROTATOR MANŞET YIRTIKLARINDA BİSEPS TENDON PATOLOJİLERİNİN SAPTANMASINDA PREOPERATİF MR'İN ETKİNLİĞİ: MR VE İNTRAOPERATİF BULGULARIN KORELASYONU

Ahmet Çağdaş BİÇEN<sup>1</sup>, Meriç ÜNAL<sup>2</sup>, Ahmet EKİN<sup>1</sup>, Mustafa Hulusi ÖZKAN<sup>3</sup>

<sup>1</sup> İzmir University of Economics, Medicalpark Hospital, Department of Orthopedics and Traumatology, İzmir, TÜRKİYE

<sup>2</sup> Süleyman Demirel University, Medical Faculty, Department of Sports Medicine, Isparta, TÜRKİYE

<sup>3</sup> İzmir Dokuz Eylül University, Medical Faculty, Department of Orthopedics and Traumatology, İzmir, TÜRKİYE

**Cite this article as:** Biçen AÇ, Ünal M, Ekin A, Özkan MH. Efficacy of Preoperative MRI in Detecting Biceps Tendon Pathologies in Rotator Cuff Tears: Correlation of MRI an Intraoperative Findings. Med J SDU 2022; 29(1): 85-91.

#### Öz

#### Amaç

Bu çalışmanın amacı rotator manşet yırtığı olan hastalarda biceps lezyonlarını saptamada manyetik rezonans görüntülemenin (MRG) doğruluğunu değerlendirmektir.

#### Gereç ve Yöntem

Ocak 2012 ile Şubat 2020 arasında opere edilen toplam 168 hasta çalışmaya dahil edildi. Tüm hastalara rotator manşet yırtığı tanısı ile artroskopik cerrahi uygulandı. Tüm hastalar genel anestezi altında ve plaj sandalyesi pozisyonunda ameliyat edildi. Demografik veriler ve ameliyat öncesi MRG bulguları kaydedildi. Artroskopik bulgular standart referans olarak kabul edildi ve preoperatif MRG kayıtları ile korele edildi.

#### Bulgular

Ameliyat öncesi görüntülerde 118 (%70.2) olguda tam kat, 50 (%29.8) olguda parsiyel yırtık saptandı. Labrum/SLAP lezyonları 18 (%10,7) olguda tespit edildi.

51 (%30.4) olguda biceps patolojisi bildirilmişti. Ameliyatlar sırasında 41 (%24,4) olguda ameliyat öncesi tespit edilen lezyonların yanı sıra ek patolojiler gözlemledik. Rotator manşet ve labrum/SLAP onarımları aynı cerrahi seanslarda yapıldı. Yeni tespit edilen lezyonların çoğunluğu 26 (%15,5) vakada tespit edilen biceps lezyonlarıydı. 41 (%24.2) olguda biceps lezyonları için tenodez, tenoliz veya tenotomi uygulandı. MRG negatif olan 26 olguda LHBT cerrahisi uygulandı. Biceps lezyonları 77 (%45.8) olguda intraoperatif olarak doğrulandı; MRG'nin bu lezyonları saptamada ki doğruluğu %66,2 idi.

#### Sonuç

Biceps lezyonları omuzun sık görülen patolojileri arasındadır. Ameliyat öncesi MRG omuzun değerlendirilmesinde önemlidir, ancak MRG'nin biceps bozukluklarını tespit etmedeki etkinliği sınırlı olabilir. LHBT lezyonlarının tanı ve tedavisinde artroskopik cerrahi önemli bir rol oynar.

**Anahtar Kelimeler:** Biceps, Biceps tendonunun uzun başı, Omuz artroskopisi, Rotator manşet yırtığı

**Sorumlu yazar ve iletişim adresi /Corresponding author and contact address:** A.Ç.B. / cagdasbicen@hotmail.com

**Müracaat tarihi/Application Date:** 20.09.2021 • **Kabul tarihi/Accepted Date:** 12.10.2021

**ORCID IDs of the authors:** A.Ç.B: 0000-0002-0711-9376; M.Ü: 0000-0001-9576-5994;

A.E: 0000-0001-9302-9475; M.H.Ö: 0000-0003-1097-6608

## Abstract

### Objective

The aim of this study is to evaluate the accuracy of magnetic resonance imaging (MRI) in detecting biceps lesions in patients with rotator cuff tears.

### Material and Methods

A total of 168 patients operated on between January 2012 and February 2020 were included in the study. All the patients underwent arthroscopic surgery with the diagnosis of rotator cuff tears. All patients were operated on under general anesthesia and in the beach chair position. Demographic data and preoperative MRI findings were recorded. Arthroscopic findings were accepted as the standard reference and correlated with preoperative MRI records.

### Results

In preoperative images, full-thickness rotator cuff tears were identified in 118 (70.2%) cases and partial-thickness tears in 50 (29.8%) cases. Labrum/SLAP lesions were detected in 18 (10.7%) cases. Biceps

disorders were reported in 51 (30.4%) cases. During the surgeries, we observed additional pathologies in 41 (24.4%) cases besides the preoperatively detected lesions. Rotator cuff and labrum/SLAP repairs were performed in the same surgical sessions. The majority of newly detected lesions were biceps lesions, being identified in 26 (15.5%) cases. In 41 (24.2%) cases tenodesis, tenolysis, or tenotomy were performed for biceps lesions. LHBT surgery was performed in 26 cases with negative MRI. Biceps lesions were confirmed in 77 (45.8%) cases intraoperatively; therefore, the accuracy of MRI in detecting these lesions was 66.2%.

### Conclusion

Biceps lesions are among the common pathologies of the shoulder. Preoperative MRI is important in evaluation of the shoulder, but the efficacy of MRI may be limited in detecting biceps disorders. Arthroscopic surgery is crucial in diagnosis and treatment of LHBT lesions.

**Keywords:** Biceps, Long head of the biceps tendon, Shoulder arthroscopy, Rotator cuff tear.

## Introduction

The long head of the biceps tendon (LHBT) originates from the supraglenoid tubercle or the posterosuperior aspect of the labrum and continues through the rotator interval (1-3). The functional role of the LHBT in the shoulder joint has not been well defined (4). Biceps lesions and injuries are among the important problems of the shoulder. They lead to functional deterioration or pain (5). Pain especially occurs in the anterior aspect of the shoulder (6, 7). Biceps lesions mostly accompany subscapularis tears (8). The incidence of biceps lesions increases with the enlargement of rotator cuff tears (9). Multiple rotator cuff tears are also accused of causing increased biceps lesions because of compensation of impaired functions of rotator cuff muscles by the LHBT (9, 10). In the early stages of rotator cuff pathologies, tendinitis, mild thickening, synovitis, and functional subluxation are seen in the LHBT. In the late stages, hypertrophy, delamination, hourglass contracture, rupture, or instability of the LHBT are observed (4). When the biceps lesions are not detected and treated during rotator cuff surgeries, patients may suffer from persistent pain. Magnetic resonance imaging (MRI) has an important role in defining shoulder pathologies, but in some cases, MRI remains insufficient in detecting biceps lesions (11). In preoperative imaging, while evaluating rotator

cuff pathologies, biceps lesions may be misinterpreted and this affects the outcomes of treatments. Due to the oblique orientation and small dimension in the rotator interval, detection of the LHBT by MRI is difficult and the literature reports that arthroscopy is superior for detecting tears of the LHBT. In recent studies secondary signs are considered in order to detect lesions of the LHBT by MRI preoperatively (6, 12). Rates of biceps injuries accompanying rotator cuff tears have been investigated, but lesions of the LHBT detected during arthroscopy and those misdiagnosed in preoperative MRI images have not been studied. We aimed to compare our perioperative findings of biceps lesions with preoperative MRI findings in a group of patients who underwent arthroscopic repair with a diagnosis of rotator cuff tear. It was hypothesized in this study that; in patients with rotator cuff tear, misdiagnosis of LHBT lesions in preoperative MRI images was not so rare.

### Material and Methods

Between January 2012 and February 2020, 168 patients who underwent arthroscopic rotator cuff repair were identified retrospectively. The study was approved by İzmir Ekonomi University Health Science Research Ethics Committee (Date: 22.03.2021 / 36, Approval no: B.30.2.İEÜSB.0.05.05-20-119).

Demographics, preoperative MRI findings, and surgical data of the patients were obtained from patient files and medical records. Inclusion criteria for the study were; having rotator cuff tear and undergoing arthroscopic rotator cuff repair. Patients with history of shoulder dislocation, patient who had irreparable rotator cuff tears or shoulder arthritis, patients whose medical records were lacking and patients under 18 years of age were excluded. All patients underwent MRI preoperatively. Ruptured tendons (supraspinatus, infraspinatus, subscapularis, teres minor) and type of rupture (partial thickness or full thickness) were identified for each patient from the preoperative MRI results. Accompanying lesions including those of the biceps tendons and labrum were also recorded for each patient. Arthroscopic shoulder operations were performed with a 30° arthroscope in beach chair position in our clinic. Initial arthroscopic visualization was conducted through a posterior portal and diagnostic arthroscopy was completed, examining the rotator cuff tendons, labrum, biceps tendon, and cartilage. Degenerations, tendinitis, and ruptures were recorded for the rotator cuff tendons, biceps tendon, and labrum. Existence of subacromial bursitis or impingement was also noted and subacromial decompression was added to the procedure. Ruptures of the rotator cuff tendons and labrum were repaired. For the lesions of the LHBT, tenotomy, tenodesis, or tenolysis was performed. All of the mentioned procedures were completed in the same surgical session. For this study, data of surgeries were extracted from patient files and medical records. Surgical findings of rotator cuff tears were noted for each tendon as partial thickness or full thickness. Degeneration and tendinitis were also noted for the rotator cuff tendons. Degeneration and ruptures were recorded for the labrum. Pathologic changes of the LHBT were noted as tendinitis and tears (partial thickness or full thickness). Additionally, the existence of subacromial bursitis or impingement was recorded. We compared the preoperative MRI findings of the patients with the arthroscopic findings. Pathologies that were detected during arthroscopic surgery but were not mentioned in preoperative MRI reports were identified. For the analysis, percentages and mean values were used.

## Results

The study group comprised 168 patients who underwent arthroscopic rotator cuff repair. The mean age of the patients was 56 (23-83) years, 96 (57.1%) of the patients were women, and 72 (42.9%) were men. In 57 (33.9%) cases, the left shoulder was operated on, and in 111 (66.1%) cases the right. The operations

were performed by 2 senior surgeons those were specialized in shoulder arthroscopy. Double-row repair was performed for rotator cuff tears. For all patients, a rotator cuff tear was reported in the preoperative MRI, and 118 (70.2%) patients had full-thickness ruptures. Full-thickness ruptures were present in the supraspinatus tendon in 115 cases, in the infraspinatus tendon in 1 case, and in the subscapularis tendon in 5 cases. Partial-thickness ruptures were identified in 50 (29.8%) patients, 48 of whom had partial-thickness ruptures in the supraspinatus tendon, 11 in the subscapularis tendon and 1 in the infraspinatus tendon. Rotator cuff tendinitis was reported in 76 (45.2%) cases by preoperative MRI. The tendon most affected by tendinitis was the subscapularis tendon in 41 cases, followed by the infraspinatus tendon in 33 cases and the supraspinatus in 2 cases. Lesions of the biceps tendon were additionally reported in 51 (30.4%) cases. Labrum/SLAP degeneration or tears were identified in 18 (10.7%) cases. Impingement or subacromial bursitis was reported in MRI in 136 (81%) cases (Table 1).

While repairing rotator cuff tears, accompanying lesions were also treated in the same surgical session for all patients. Subacromial decompression or acromioplasty was performed for 159 (94.6%) patients, 5 (3%) patients underwent labrum/SLAP repair, and 4 (2.4%) patients underwent SLAP debridement. Forty-one (24.4%) patients needed an additional approach to the biceps. In 18 cases tenodesis, in 16 cases tenotomy, and in 7 cases tenolysis was performed (Table 2) (Figure 1-2). Tenotomy was preferred in patients older than 60 years old or with presence of more degenerative tendinosis. Tenodesis was preferred in younger and high demand patients. Tenolysis was preferred for patients who had fibrillations in LHBT. For tenodesis small-incision open, subpectoral soft tissue technique was used.

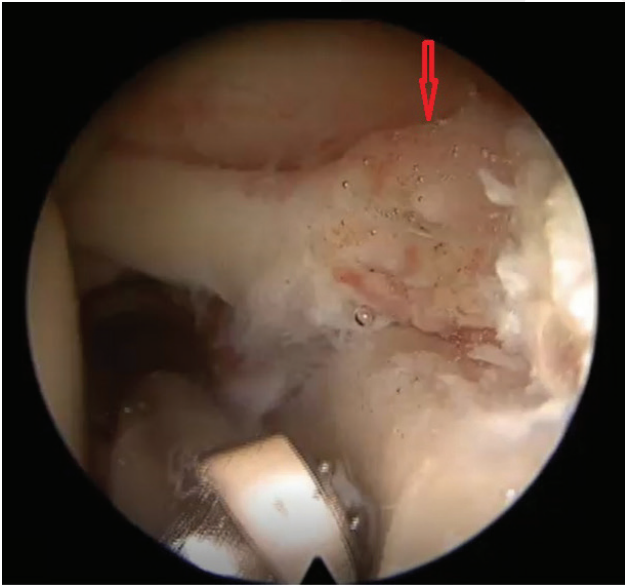
We observed a significant number of lesions detected during arthroscopic surgery that were not reported in preoperative imaging. In 41 (24.4%) cases, an additional lesion was visualized during arthroscopy. Most of the newly detected lesions were biceps pathologies (26 cases; 15.5% of all and 63.4% of newly detected), followed by infraspinatus (8 cases; 4.8% of all and 19.5% of newly detected), subscapularis (5 cases; 3% of all and 12.2% of newly detected), and teres minor ruptures (2 cases; 1.2% of all and 4.2% of newly detected) (Table 3).

We realized that the majority of our surgeries for biceps lesions were performed for patients whose

**Table 1** Preoperative MRI findings

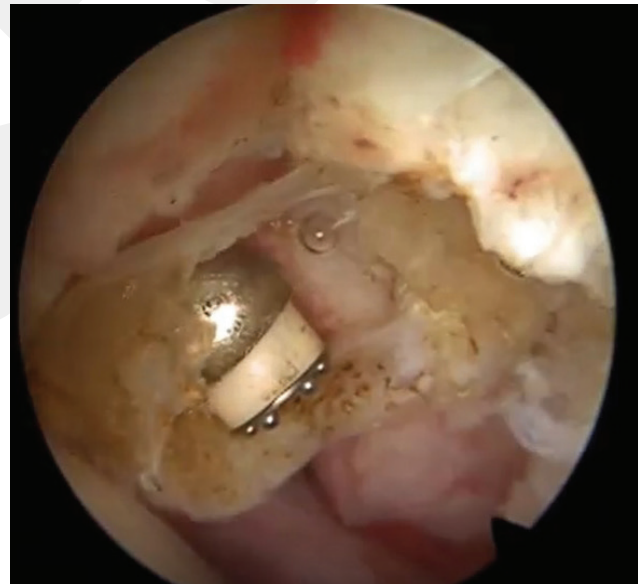Preoperative findings	n=168	%
<b>Rotator Cuff Full-Thickness Rupture</b>	118	70.2
SS	115	68.5
IS	1	0.6
Subs	5	3
<b>Rotator Cuff Partial-Thickness Rupture</b>	50	29.8
SS	48	28.6
IS	1	0.6
Subs	11	6.5
<b>Biceps Tendinitis</b>	51	30.4
<b>Rotator Cuff Tendinitis</b>	76	45.2
SS tendinit	2	1.2
IS tendinit	33	19.6
Subs tendinit	41	24.4
<b>Labrum lesion</b>	18	10.7
<b>Impingement</b>	136	81

MRI: magnetic resonance imaging; SS: supraspinatus; IS: infraspinatus; Subs: subscapularis

**Figure 1:**

Arrow shows partial rupture and degeneration of biceps tendon.

biceps lesions were not detected preoperatively. Preoperatively, a total of 51 patients were found to have biceps pathologies by MRI. Only 15 (29.4%) of these patients had an approach to the biceps tendons. Of 41 patients who underwent biceps procedures,

**Figure 2:**

Tenotomy of biceps tendon using radiofrequency ablator.

15 (36.6%) had preoperatively reported lesions by MRI and 26 (63.4%) had no lesions reported in preoperative imaging (Table 4). Surgeons were aware of the MRI results, but the records were evaluated by two radiologists in blinded fashion.

**Table 2** Performed surgeries

Surgery	n	%
<b>Rotator cuff repair</b>	168	100
<b>Biceps surgery</b>	41	24.4
Tenodesis	18	10.7
Tenotomy	16	9.5
Tenolysis	7	4.2
<b>Labrum repair</b>	5	3
<b>Subacromial decompression-Acromioplasty</b>	159	94.6

**Table 3** Peroperative findings added to preoperative MRI findings

New pathologies detected during arthroscopy	n=41	% Overall (168)	% Detected
<b>Biceps pathology</b>	26	15.5	63.4
<b>Infraspinatus rupture</b>	8	4.8	19.5
<b>Subscapularis rupture</b>	5	3	12.2
<b>Teres minor rupture</b>	2	1.2	4.2

MRI: magnetic resonance imaging.

**Table 4** Number of operations performed for biceps pathologies

Number of biceps surgeries	n	Mean age of the patients	Detected in MRI before surgery n	Not detected preoperatively n
<b>Biceps surgery (total)</b>	41	59.5	15/%36.6	26/63.4
Tenodesis	18	57.1	8	10
Tenotomy	16	61.7	5	11
Tenolysis	7	60.6	2	5

MRI: magnetic resonance imaging.

## Discussion

Rotator cuff ruptures are among the common causes of pain of the shoulder. Conservative and surgical treatment options are available. Accompanying lesions are not rare in cases of shoulder pathologies. When the accompanying lesions are not treated, persistent postoperative pain and unsatisfactory functional outcomes may result (13). LHBT lesions were

defined to occur together with rotator cuff ruptures in the literature (14). MRI is performed preoperatively for most of these patients to plan the treatment. In order to prevent insufficient surgery, preoperatively identifying all lesions by imaging is quite important, but it is known that biceps lesions may not always be identified by MRI. The shoulder MRI protocol designed for imaging rotator cuff tears, partial volume artifacts, and signal intensity are blamed for the insufficiency

of MRI in detecting LHBT disorders (15). Walch et al. claimed that this may be due to the dynamic condition of the biceps (16). Lesions of biceps undiagnosed with static MRI may be visualized dynamically during arthroscopy. Misdiagnosis of LHBT disorders is especially common in preoperative images while treating rotator cuff tears. In rotator cuff surgeries, treatment of LHBT lesions is mainly performed with tenodesis or tenotomy (17). In the literature, the existence of LHBT disorders accompanying rotator cuff tears has been widely evaluated. In our study we observed that most misdiagnosed disorders accompanying rotator cuff tears were biceps lesions. We also saw that MRI did not reveal signs of LHBT lesions for most of the patients who needed tenotomy or tenodesis. We wanted to compare the preoperative and perioperative status of LHBT disorders in our group of patients.

Desai et al. conducted a study to evaluate clinical outcomes of patients treated arthroscopically for rotator cuff tears (18). Their study included patients with full-thickness rotator cuff tears. While repairing rotator cuff tears, tenotomy of the LHBT was also performed in cases in which LHBT lesions existed. They reported that, in their study group, 51 of 141 patients had accompanying LHBT lesions with a rate of 36.1%. In our study the rate of accompanying LHBT lesions was 45.8%.

In 2012 Chen et al. investigated the relation of LHBT and SLAP lesions with complete rotator cuff tears (9). They suggested that SLAP lesions were also a part of LHBT disorders. They classified the LHBT pathologies in a group of patients who underwent arthroscopic rotator cuff repair, dividing LHBT lesions into 6 types. The sixth type was SLAP lesions. While 76% of the patients showed signs of LHBT lesions, 6% of the patients had SLAP lesions. The rates of LHBT lesions were lower in our study compared to the findings of Chen et al.

In the study of Lee et al., 80 patients who underwent arthroscopic rotator cuff repair were evaluated (19). These authors investigated the efficacy of MRI in detecting LHBT lesions accompanying rotator cuff tears. They found during arthroscopic surgery that 40 (50%) of the patients had LHBT tears along with rotator cuff tears. Thirty-five patients had partial and 5 patients had total tears of the LHBT. MRI sensitivity and specificity in detecting partial tears were found to be between 70% and 80%, but for total tears MRI sensitivity and specificity were between 80% and 100%. The involvement of LHBT disorders in rotator cuff tears was similar in our study.

Accuracy of MRI in detecting shoulder pathologies preoperatively was evaluated by Houtz et al. (20). In their study, 69 MRI results and 35 MR arthrograms of 100 patients were examined preoperatively and compared with arthroscopic findings. They recorded rotator cuff, labrum, and biceps pathologies in both preoperative images and perioperative findings. Their study showed the accuracy of detecting subluxations, dislocations, and tears of the LHBT to be 73-78%. Another study published by Kang et al. in 2017 addressed the success of MR arthrography in defining biceps lesions preoperatively (21). The study included 101 patients who had rotator cuff tears and underwent arthroscopic surgery. Arthroscopic findings were accepted as the standard reference and correlated with preoperative images retrospectively. The accuracy of MRI was reported to be 66.3-74.3% in this study. In our patient group we found a concordant value of preoperative MRI detecting LHBT lesions at 66.2%.

In 2015 Razmjou et al. published a similar study comparing the accuracy of MRI with arthroscopy in detecting biceps disorders accompanying rotator cuff pathologies (22). Their study included 183 patients who underwent rotator cuff surgery. They found that for 54% of the patients with full-thickness biceps tears equivalent findings could be identified with preoperative MRI. In another study the accuracy of MRI in detecting biceps lesions was evaluated in 66 patients who all had preoperatively suspected biceps or SLAP pathologies based on physical examinations (23). Arthroscopy showed that 97% of the patients had rotator cuff tears. It was reported that the integrity of the biceps was not lost in only 7 cases. Only 23 of the patients could be diagnosed correctly by preoperative MRI with a concordance rate of 34.9%. Although biceps lesions could be detected at higher rates in our study, the success in predicting pathologies before surgeries was still meaningfully low.

The presented study has some limitations. The first limitation is its retrospective design. Second, a limited number of patients were evaluated. Another issue was the absence of control cases. Fourth, the operations were not performed by a single surgeon. This might have led to differences in defining and evaluating disorders during the arthroscopic surgeries. There was also no microscopic control of the ruptured tendons, consequently we cannot clearly define the extent of the degeneration in tendons. Despite these limitations, the results of our study emphasize the importance of preoperative imaging in defining biceps lesions.

## Conclusion

Biceps lesions are common problems accompanying rotator cuff tears. Degenerations, tendinitis, and tears of the biceps can be treated arthroscopically. Although preoperative MRI is very important in shoulder pathologies, MRI may be limited in detecting biceps disorders. In preoperative planning and during surgery, lesions of the biceps have to be considered carefully. Arthroscopy has a crucial role in diagnosis and treatment of LHBT lesions. Tenodesis, tenotomy or tenolysis can be chosen for biceps lesions. Attention has to be paid to biceps images in order to prevent persistent postoperative pain and poor functional results.

## Conflict of Interest Statement

The authors have no conflicts of interest to declare.

## Ethical Approval

The study was approved by İzmir Ekonomi University Health Science Research Ethics Committee (Date: 22.03.2021 / 36, Approval no: B.30.2.İEÜSB.0.05.05-20-119).

## Funding

This research did not receive any specific grant from funding agencies in the public, commercial, or not-for-profit sectors.

## Authors Contributions

ÇB: Writing-Original draft preparation

MÜ: Methodology, Writing-Reviewing and Editing

MÖ: Investigation, Editing

AE: Investigation, Editing

## References

- Morag Y, Bedi A, Jamadar DA. The rotator interval and long head biceps tendon: anatomy, function, pathology, and magnetic resonance imaging. *Magn Reson Imaging Clin N Am*. 2012; 20: 229-259.
- Lee JC, Guy S, Connell D, Saifuddin A, Lambert S. MRI of the rotator interval of the shoulder. *Clin Radiol*. 2007; 62: 416-423.
- Vangsness CT Jr, Jorgenson SS, Watson T, Johnson DL. The origin of the long head of the biceps from the scapula and glenoid labrum. An anatomical study of 100 shoulders. *J Bone Joint Surg Br*. 1994; 76: 951-954.
- Virk MS, Cole BJ. Proximal Biceps Tendon and Rotator Cuff Tears. *Clin Sports Med*. 2016; 35:153-161.
- Watson ST, Robbins CB, Bedi A, Carpenter JE, Gagnier JJ, Miller BS. Comparison of outcomes 1 year after rotator cuff repair with and without concomitant biceps surgery. *Arthroscopy*. 2017; 33: 1928-1936.
- Takahashi N, Sugaya H, Matsuki K, Miyauchi H, Matsumoto M, Tokai M, Onishi K, Hoshika S, Ueda Y. Hypertrophy of the extra-articular tendon of the long head of biceps correlates with the location and size of a rotator cuff tear. *Bone Joint J*. 2017; 99: 806-811.
- Singaraju VM, Kang RW, Yanke AB, McNickle AG, Lewis PB, Wang VM, Williams JM, Chubinskaya S, Romeo AA, Cole BJ. Biceps tendinitis in chronic rotator cuff tears: a histologic perspective. *J Shoulder Elbow Surg*. 2008; 17: 898-904.
- Beall DP, Williamson EE, Ly JQ, Adkins MC, Emery RL, Jones TP, et al. Association of biceps tendon tears with rotator cuff abnormalities: degree of correlation with tears of the anterior and superior portions of the rotator cuff. *AJR Am J Roentgenol*. 2003; 180: 633-639.
- Chen CH, Chen CH, Chang CH, Su CI, Wang KC, Wang IC, Liu HT, Yu CM, Hsu KY. Classification and analysis of pathology of the long head of the biceps tendon in complete rotator cuff tears. *Chang Gung Med J*. 2012; 35: 263-270.
- Toshiaki A, Itoi E, Minagawa H, et al. Cross-sectional area of the tendon and the muscle of the biceps brachii in shoulders with rotator cuff tears: a study of 14 cadaveric shoulders. *Acta Orthop*. 2005; 76: 509-512.
- Mohtadi NG, Vellet AD, Clark ML, Hollinshead RM, Sasyniuk TM, Fick GH, Burton PJ. A prospective, double-blind comparison of magnetic resonance imaging and arthroscopy in the evaluation of patients presenting with shoulder pain. *J Shoulder Elbow Surg*. 2004; 13: 258-265.
- Lafosse L, Reiland Y, Baier GP, Toussaint B, Jost B. Anterior and posterior instability of the long head of the biceps tendon in rotator cuff tears: a new classification based on arthroscopic observations. *Arthroscopy*. 2007; 23: 73-80.
- Popp D, Schöffl V. Superior labral anterior posterior lesions of the shoulder: Current diagnostic and therapeutic standards. *World J Orthop*. 2015; 6: 660-671.
- Cervilla V, Schweitzer ME, Ho C, Motta A, Kerr R, Resnick D. Medial dislocation of the biceps brachii tendon: appearance at MR imaging. *Radiology*. 1991; 180: 523-526.
- Baptista E, Malavolta EA, Gracitelli MEC, Alvarenga D, Bordalo-Rodrigues M, Ferreira Neto AA, de Barros N. Diagnostic accuracy of MRI for detection of tears and instability of proximal long head of biceps tendon: an evaluation of 100 shoulders compared with arthroscopy. *Skeletal Radiol*. 2019; 48: 1723-1733.
- Walch G, Nove-Josserand L, Levigne C, Renaud E. Tears of the supraspinatus tendon associated with "hidden" lesions of the rotator interval. *J Shoulder Elbow Surg*. 1994; 3: 353-360.
- Leroux T, Chahal J, Wasserstein D, et al. A systematic review and meta-analysis comparing clinical outcomes after concurrent rotator cuff repair and long head biceps tenodesis or tenotomy. *Sports Health*. 2015; 7: 303-307.
- Desai SS, Mata HK. Long Head of Biceps Tendon Pathology and Results of Tenotomy in Full-Thickness Repairable Rotator Cuff Tear. *Arthroscopy*. 2017; 33: 1971-1976.
- Lee RW, Choi SJ, Lee MH, Ahn JH, Shin DR, Kang CH, Lee KW. Diagnostic accuracy of 3T conventional shoulder MRI in the detection of the long head of the biceps tendon tears associated with rotator cuff tendon tears. *Skeletal Radiol*. 2016; 45: 1705-1715.
- Houtz CG, Schwartzberg RS, Barry JA, Reuss BL, Papa L. Shoulder MRI accuracy in the community setting. *J Shoulder Elbow Surg*. 2011; 20:537-542.
- Kang Y, Lee JW, Ahn JM, Lee E, Kang HS. Instability of the long head of the biceps tendon in patients with rotator cuff tear: evaluation on magnetic resonance arthrography of the shoulder with arthroscopic correlation. *Skeletal Radiol*. 2017; 46: 1335-1342.
- Razmjou H, Fournier-Gosselin S, Christakis M, Pennings A, El-Maraghy A, Holtby R. Accuracy of magnetic resonance imaging in detecting biceps pathology in patients with rotator cuff disorders: comparison with arthroscopy. *J Shoulder Elbow Surg*. 2016; 25: 38-44.
- Dubrow SA, Streit JJ, Shishani Y, Robbin MR, Gobeze R. Diagnostic accuracy in detecting tears in the proximal biceps tendon using standard nonenhancing shoulder MRI. *Open Access J Sports Med*. 2014; 5: 81-87.