

Original Article

Auditory and Histopathological Effects of Topical Mercurochrome Treatment in Rats with Tympanic Membrane Perforation

Süleyman Korkmaz , Mehmet Emrah Ceylan , Gözde Ceylan , Abdullah Dalgıç ,
Sevinç İnan , Levent Olgun , Mehmet Ziya Özür 

Department of Otorhinolaryngology, Health Sciences University, İzmir Bozyaka Training and Research Hospital, İzmir, Turkey (SK, MEC, GC, AD, LO, MZÖ)
Department of Histology and Embryology, İzmir Economy University School of Medicine, İzmir, Turkey (Sİ)

ORCID IDs of the authors: S.K. 0000-0001-9069-8913; M.E.C. 0000-0001-7330-9306; G.C. 0000-0001-9318-4547; A.D. 0000-0002-6958-4169; S.İ. 0000-0003-1971-9720; L.O.0000-0001-6389-1216; M.Z.Ö. 0000-0003-3611-7908.

Cite this article as: Korkmaz S, Ceylan ME, Ceylan G, Dalgıç A, İnan S, Olgun L, et al. Auditory and Histopathological Effects of Topical Mercurochrome Treatment in Rats with Tympanic Membrane Perforation. J Int Adv Otol 2019; 15(1): 22-7.

OBJECTIVES: Topical treatment is first choice in the treatment of uncomplicated chronic otitis media. It was intended to assess auditory and histopathological safety of ototopical use of mercurochrome solution in rats with induced tympanic membrane perforation.

MATERIALS and METHODS: The study was conducted on 21 female Wistar-Albino rats which were randomly assigned into 3 groups. In all rats, perforation was performed at right tympanic membrane. Distortion product otoacoustic emissions (DPOAEs) measurements were performed at frequencies of 2000, 3000 and 4000 Hz (with L1/L2: 70 /70 dB at 2f1-f2 frequency; f2/f1 ratio: 1:22) before recovery from anesthesia and signal-to-noise ratio (SNR) were recorded. Normal saline, 2% mercurochrome and gentamicin were given to group 1, 2 and 3 twice daily over a week, respectively. Rats were sacrificed after DPOAE measurements on day 14. Right temporal bone specimens were examined under light microscope after processing.

RESULTS: Based on DPOAE results, there was no significant difference among groups before treatment. On day 14, significant differences were found in DPOAE measurements at 3000 and 4000 Hz, and in mean SNR values in 2% mercurochrome and gentamicin groups when compared to normal saline group while no significant difference was detected at 2000 Hz among groups. In addition, significant degeneration was detected in Corti organs, spiral ganglions and stria vascularis in groups 2 and 3.

CONCLUSION: In this study, it was observed that mercurochrome use in external otitis and otitis media with tympanic membrane perforation could cause ototoxicity and concluded that the solution should be used cautiously.

KEYWORDS: Merbromin, rats, tympanic membrane perforation, signal-to-noise ratio, ototoxicity

INTRODUCTION

Topical treatment is the first choice in the treatment of uncomplicated, chronic otitis media, and in inflammatory or infectious disorders of the external auditory channel ^[1]. Azole antifungals, aluminum acetate, ciclopirox olamine, boric acid, nystatin, and mercurochrome are commonly used in topical antifungal therapy ^[2].

Mercurochrome (2-7-dibromo-4-hydroxy-mercury fluorescein) is an organic mercuric compound that is neurotoxic when given systemically. In some studies, it was shown that several mercuric compounds cause ototoxicity in systemic administration ^[3-6]. For similar reasons, use of mercurochrome was prohibited by The United States Food and Drug Administration. However, it is still used in refractory otomycosis and local infection via topical route ^[7,8]. To best of our knowledge, there is no study on passage of mercurochrome across round window and ototoxicity potential in topical administration.

The aim of this study was to investigate the potential ototoxic effect of mercurochrome on outer hair cells by measuring distortion product otoacoustic emissions (DPOAE), and to demonstrate the possible histopathological changes in cochlea in rats with induced tympanic membrane perforation.

This study was presented orally at the 2nd National Congress of Otology and Neurotology, 10-13 May 2012, Antalya, Turkey.

Corresponding Address: Mehmet Emrah Ceylan E-mail: mrhcyln@gmail.com

Submitted: 04.04.2018 • Revision Received: 09.08.2018 • Accepted: 23.08.2018 • Available Online Date: 27.11.2018

©Copyright 2019 by The European Academy of Otology and Neurotology and The Politzer Society - Available online at www.advancedotology.org

MATERIALS and METHODS

The study was approved by the Ethics Committee of Ege University on Experimental Animal Trials (approval date: 23.12.2011; Approval: 2011-189). Surgical intervention and auditory tests were performed at the Animal Laboratory of Ege University, Experimental Surgery Department. The study was conducted in accordance to The Turkish Animal Protect Act (Act 5199), Turkish Republic Ministry of Food, Agriculture and Livestock regulations on protection of laboratory animals used for experimental or other scientific purposes, and procedures and principles for development, operation, and audition of laboratory animal production and laboratories for experiments, and Helsinki Declaration.

The study was conducted on 21 female, healthy Wistar-Albino rats (weighing 200-250 g). Rats were randomly assigned into three groups. Normal saline was given to group 1 (negative control group), 2% mercurochrome solution to group 2 (study group), and gentamicin to group 3 (positive control group). Throughout the experiments, all rats were kept in an environment with noise level below 50 dB, and temperature of 21-22°C under 12:12 light:dark cycle. Food and tap water were provided ad libitum.

Anesthesia

In all rats, general anesthesia was administered by 35 mg/kg ketamine hydrochloride (Ketalar Pfizer, İstanbul, Turkey) plus 5 mg/kg xylazine (Rompun, Bayer, İstanbul, Turkey) via intraperitoneal route. No additional anesthesia was required.

Surgical Intervention

In all rats, right tympanic membrane was visualized by surgical microscope. No external otitis and/or otitis media or tympanic membrane perforation was observed. To prevent its potential effects on DPOAE measurements, no antiseptic solution was used before the surgical intervention. A central perforation was created by using a sharp needle, which was not greater than half of tympanic membrane. A hemostatic sponge gel (Spongostan Standard, Johnson & Johnson Medical, Skipton, United Kingdom) was placed into the middle ear cavity as being over membrane of round window.

Topical Intervention

First topical administration was performed following DPOAE measurement under anesthesia. In group 1, 0.1 mL normal saline (Serum Fizyolojik 0.9% Vial, Adeka Medical, Samsun, Turkey); in group 2, 0.1 mL 2% mercurochrome solution (Mersol antiseptik çözelti, Merkez Medical, İstanbul, Turkey); and in group 3, 0.1 mL gentamicin solution (40mg/mL) (Genta ampul, İ.E. Ulagay Medical, İstanbul, Turkey) was applied to external auditory canal twice a day over a week.

Auditory Evaluation

In all rats, emissions of right ear were measured immediately after the surgical trauma on day 1, and after surgery by DPOAE on day 14. The SNR values were measured at 2000 Hz, 3000 Hz and 4000 Hz, and arithmetic mean for three frequencies were calculated. Measurements were performed by GSI AUDEA® System (Grason-Stadler Inc., Madison, United States of America) and ear-canal probe produced for premature infants. Measurements were performed after confirming the appropriate configuration of probe indicator on the device and stimulus waveform as well as appropriate positioning

for measurement. Since DPOAE measurement at 65/55 dB failed in some subjects, measurements were performed at 70/70 dB. The SNR values were recorded at 2000 Hz, 3000 Hz, and 4000 Hz (with L1: 70 dB; L2: 70 dB at 2f1-f2 frequency; f2/f1 ratio: 1:22) by DPOAE. On day 14, DPOAE measurements were repeated under general anesthesia for the right ear with 35 mg ketamine hydrochloride (35 mg/kg) plus xylazine (5 mg/kg).

Study Protocol

On day 14, all rats were sacrificed after hearing assessment under general anesthesia by injection of lethal dose of ketamine hydrochloride. Right temporal lobe was dissected, and was transferred to formalin solution for histopathological examination. Sequential sections were decalcified, then rehydrated following deparaffinization, and stained by hematoxylin-eosin (H-E, Surgipath, Peterborough, United Kingdom). Following staining, organ of corti (hydropic and vacuolar degeneration), spiral ganglion (cytoplasmic and nuclear condensation, nucleus and neuron loss), and stria vascularis (edema and vacuolization) were examined under the light microscope using high magnification (x400). According to the percentage of degenerated cells, degeneration was rated as follows: 0, no degeneration; 1, mild degeneration (25%); 2, moderate degeneration (25%–75%); and 3, severe degeneration (75%-100%).

Statistical Analysis

The Kolmogorov–Smirnov test was used to assess normal distribution of degeneration grades in histopathological examination. One-way Anova test was used to assess differences among degeneration grades of groups. Post-hoc DUNN test was used to compare the study, negative control, and positive control groups to determine groups with significant difference. All auditory and histopathological findings were analyzed by the Statistical Package for Social Sciences version 16.0 (SPSS Inc., Chicago, IL, USA).

RESULTS

In our study, no tympanic membrane perforation or findings of otitis media was observed in otomicroscopic examination before auditory tests. On day 14, it was seen that tympanic membrane perforation was maintained in all rats, and no finding of otitis media or external otitis was detected in any rat.

Auditory Findings

Table 1 presents mean and median emission values recorded by DPOAE.

Analysis of Auditory Findings

In all groups, similarity of values obtained on day 1 and 14 were tested by Kruskal–Wallis test. A p value < 0.05 was considered statistically significant. It was found that there was no significant difference regarding DPOAE measurements and mean values on day 1, while there were significant differences in mean values and DPOAE measurements at 3000 Hz and 4000 Hz between the groups on day 14. To determine the groups displaying difference, binary comparisons were performed by the Mann–Whitney U test. P value was set as < 0.017 since three tests were performed to determine differences in binary comparisons. No significant difference was found in DPOAE measurements at 2000 Hz between groups (Table 2).

Table 1. Mean and median SNR values on day 1 and 14 in the groups

	Day 1 2000 Hz	Day 1 3000 Hz	Day 1 4000 Hz	Day 1 Average	Day 14 2000 Hz	Day 14 3000 Hz	Day 14 4000 Hz	Day 14 Average
Group 1 (Negative control)	Mean±SD 11.5±4	18±2.9	14.2±6.7	14.5±1.6	13.6±4.8	19.8±5.4	16.3±9.6	17.6±5.1
	Median (Min-Max) 11.5 (2.9-16.4)	18.7 (12.8-21)	11.5 (6.7-24.8)	14.4 (12.2-16.9)	16.3 (7.5-18.9)	21.7 (9.6-28.1)	19.6 (7.8-32.3)	19.1 (9.3-24.3)
Group 2 (Mercurochrome)	Mean ±SD 12.3±6.8	20.3±9.5	15.3±5.7	16±4.7	9.6±5.2	9.4±1.7	7±4.1	8.7±2.3
	Median (Min-Max) 10 (6.7-28.6)	19.7 (9.4-39.5)	13.9 (7.5-24.2)	15 (8.8-25.2)	6.9 (6.3-22.1)	10.2 (7.4-11.7)	6.7 (0-13)	9.1 (4.7-12)
Group 3 (Positive control)	Mean±SD 10.5±4.9	14.5±1.9	15±6.7	13.3±3	9.9±8.2	8.6±1.9	4.6±4.9	7.7±3.2
	Median (Min-Max) 11.4 (0-17.8)	14.2 (11.8-17.3)	16.2 (0-21.6)	14.3 (7.7-16.8)	7.5 (0-27.5)	8.4 (5.7-11.8)	4.8 (0-15.1)	6.7 (4.8-14.1)

SD: Standard Deviation; Min: Minimum; Max: Maximum; Hz: Hertz

Table 2. Relationship between groups according to the frequencies on day 1 and 14

GROUPS	Day 1 Kruskal-Wallis*				Day 14 Mann-Whitney U**			
	2000 Hz	3000 Hz	4000 Hz	Average	2000 Hz	3000 Hz	4000 Hz	Average
Group 1-2-3	p=0.610	p=0.187	p=0.809	p=0.558	p=0.243	p=0.005	p=0.007	p=0.007
Group 1-2	p>0.05	p>0.05	p>0.05	p>0.05	p>0.017	p=0.007	p=0.011	p=0.004
Group 1-3	p>0.05	p>0.05	p>0.05	p>0.05	p>0.017	p=0.004	p=0.006	0.009
Group 2-3	p>0.05	p>0.05	p>0.05	p>0.05	p>0.017	p=0.710	p=0.318	p=0.535

Hz: Hertz

*Significance level is set as <0.0

** Significance level is set as 0.017

Table 3. Comparison of the frequencies on day 1 and 14 within group

Groups	2000 Hz		3000 Hz		4000 Hz		Average
	Day 1	Day 14	Day 1	Day 14	Day 1	Day 14	
Group 1	p=0.482		p=0.225		p=0.224		p=0.277
Group 2	p=0.180		p=0.021		p=0.018		p=0.009
Group 3	p=0.522		p=0.002		p=0.025		p=0.013

Hz: Hertz

On day 14, significant differences were found in mean values and DPOAE measurements at 3000 Hz and 4000 Hz between groups 1 and 2, and between groups 1 and 3. However, no significant difference was found in mean values and DPOAE measurements at 3000 and 4000 Hz between groups 2 and 3 (Table 2).

The Mann–Whitney U test was used to compare values obtained at day 1 and 14. A p value<0.05 was considered statistically significant. In group 1, no significant difference was detected in mean values and DPOAE measurements at 2000 Hz, 3000 Hz, and 4000 Hz between days 1 and 14. In group 2, significant differences were found in mean values and DPOAE measurements at 3000 Hz and 4000 Hz between days 1 and 14, while there was no significant difference in DPOAE measurements at 2000 Hz. In group 3, significant differences were found in mean values and DPOAE measurements at 3000 Hz and 4000 Hz between days 1 and 14, while there was no significant difference in DPOAE measurements at 2000 Hz (Table 3).

Histopathological Findings

In group 1, cochlea was considered to have normal histology in the microscopic examination. No degeneration was detected in organ of corti, spiral ganglion, and stria vascularis (Table 4). Moderate-to-severe disruption in cellular arrangement of organ of corti, hydropic and vacuolar degeneration, loss of inner and outer hair cells, chromatolysis in spiral ganglion cells, cytoplasmic and nuclear conden-

sation, reduction in number of nuclei and neurons, irregular satellite cells, and hydropic and vacuolar degeneration in stria vascularis in groups 2 (Figure 1-2) and 3.

Analysis of Histopathological Findings

Kolmogorov–Smirnov test found that the distribution of degeneration grades was normal after the histopathological examination. By one-way Anova test, it was found that there was significant difference in degeneration grades of all parameters (organ of corti, spiral ganglion, and stria vascularis) among the three groups (p<0.05). To determine groups with significant difference, post-hoc Dunnel test was used to compare study, negative control, and positive control groups. It was found that degeneration in organ of corti, spiral ganglion, and stria vascularis was significantly more severe in the study group (received mercurochrome) when compared to that in negative controls (received normal saline) (organ of corti, p=0.001; spiral ganglion, p=0.002; and stria vascularis, p=0,001). No significant difference was detected in degeneration in all three regions between the study group and the positive controls (received gentamicin) (organ of corti, p=0.429; spiral ganglion, p=0.940; and stria vascularis, p=0,437)

DISCUSSION

Topical drug administration is an inexpensive method with fewer side effects. It is highly effective in disorders of external and middle ear due to advantage of achieving high tissue concentrations [9].

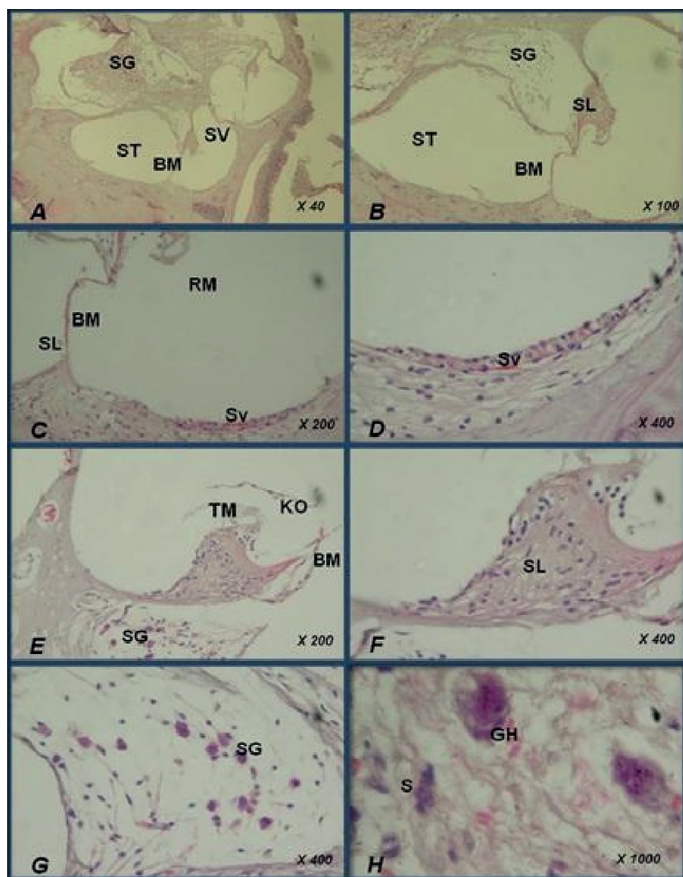


Figure 1. Cochlear sections of subject 1 from mercurochrome group. Severe involvement is seen in organ of corti, spiral ganglion cells, and stria vascularis (Grade 2 degeneration)
 ST: Scala tympani; SV: Scala vestibule; SG: Spiral ganglion; SL: Spiral limbus; KO: Organ of corti; BM: Basilar membrane; RM: Reissner’s membrane; Sv: Stria vascularis; TM: Tectorial membrane; GH: Ganglion cell (neuron); S: Satellite cell

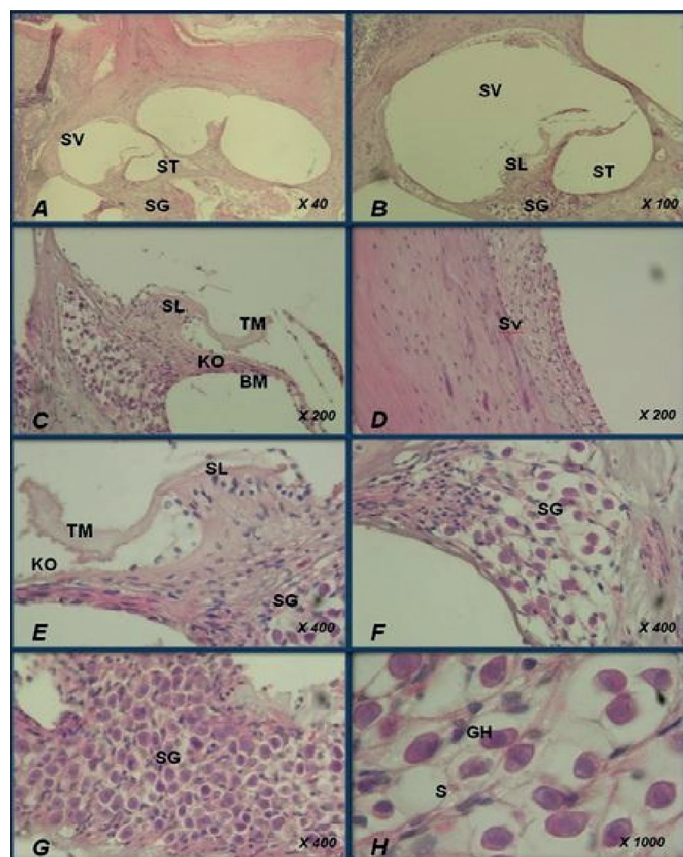


Figure 2. Cochlear sections of subject 3 from mercurochrome group. Moderate involvement is seen organ of corti, spiral ganglion cells, and stria vascularis (Grade 3 degeneration)
 ST: Scala tympani; SV: Scala vestibule; SG: Spiral ganglion; SL: Spiral limbus; KO: Organ of corti; BM: Basilar membrane; RM: Reissner’s membrane; Sv: Stria vascularis; TM: Tectorial membrane; GH: Ganglion cell (neuron); S: Satellite cell

However, there is still risk for ototoxicity in case of tympanic membrane perforation [10].

In large series, success rate of topical treatment has been reported to as 93.4-95.8% for mercurochrome [11, 12]. Thus, it is preferred in the topical treatment of refractory otomycosis in particular. To best of our knowledge, there is no study in the literature reporting that topical mercurochrome administration can lead to ototoxicity.

In our study, topical mercurochrome administration resulted in significant decrease in the SNR values at 3000 Hz and 4000 Hz, but no significant difference was detected at 2000 Hz. In histopathological examination, moderate-to-severe disruption in cellular arrangement of organ of corti, chromatolysis and reduction in spiral ganglion cells,

Table 4. Histopathological findings in cochlear specimens stained with H&E

	Normal Saline n:7	Mercurochrome n:7	Gentamicin n:7
Hydropic and vacuolar degeneration in organ of corti			
	0	3	3
	0	3	3
	1	2	3
	0	2	3
	0	3	3
	0	2	3
	0	3	2
Degeneration in spiral ganglion cells			
	0	3	3
	1	3	2
	1	2	3
	0	2	3
	0	3	3
	1	2	2
	0	3	2
Hydropic and vacuolar degeneration in stria vascularis			
	0	3	2
	0	2	3
	1	2	3
	0	2	2
	0	3	3
	0	2	3
	0	3	2

Organ of corti (Hydropic and vacuolar degeneration, loss of inner and outer hair cells)
 Spiral Ganglion (Cytoplasmic and nuclear condensation, loss of nucleus and neurons)
 Stria Vascularis (Hydropic and vacuolar degeneration)
 0: No degeneration
 1: Mild degeneration
 2: Moderate degeneration
 3: Severe degeneration

irregular satellite cells, and vacuolization in stria vascularis were observed in the group given mercurochrome. Based on DPOAE results and histopathological findings, it was found that topical administration of 2% mercurochrome (0.1 mL) twice daily over 7 days leads to ototoxicity in rats with tympanic membrane perforation.

The experimental method employed in our study required to induce tympanic membrane perforation. In a study using the similar method by Ueda et al. [13] DPOAE responses could be obtained when less than half space of bulla was filled with fluid, but they couldn't be obtained when fluid completely filled bulla. It was shown that DPOAE responses decreased with increasing size of tympanic membrane perforation. In an experimental study by LeBourgeois 3rd et al. [14] it was shown that DPOAE responses could be detected despite slight decrease in the presence of myringotomy and small tympanic membrane perforations up to 25%; however, DPOAE responses were substantially decreased in perforations of 50% or larger. Zhao et al. [15] reported that DPOAE responses couldn't be obtained in patients with tympanic membrane perforation in the presence of large perforation or hearing loss above 20 dB. In a study in which topical Castellani solution was used in the rat model of tympanic membrane perforation, Gültekin et al. [16] obtained response at 80/70 dB when they failed to obtain response at 65/55 dB, reporting that Castellani solution wasn't ototoxic. In our study, DPOAE responses couldn't be obtained at 65/55 dB in some subjects; thus, DPOAE measurements were then performed at 70/70 dB. Emissions could be recorded in all subjects. No problem was experienced when recording DPOAEs in rats with induced tympanic membrane perforation.

Mercurochrome solution (antiseptic solution) used in our study consists of 2% mercurochrome, 36.4% ethyl alcohol, and 6.2% acetone. In the literature, there is no study about ototoxic potential of acetone, but ototoxicity has been investigated for varying concentrations of ethyl alcohol. In a study using boric acid plus ethyl alcohol at different concentrations, Aktaş et al. [17] reported that 40% alcohol produced results similar to those obtained by using normal saline. In a study by Morizono and Sikora et al. [18] using varying concentrations of ethyl alcohol, it was reported that 50% ethyl alcohol caused reduction in cochlear microphonics, and that ototoxicity could be observed in higher concentrations. However, in an experimental study using 70% alcohol plus 4% boric acid mixture, Öztürkcan et al. [19] reported that the mixture tested was ototoxic. In our study, 36.4% ethyl alcohol was present in the mercurochrome solution used. There is no study indicating that ethyl alcohol may have ototoxic effect at concentrations as low as 36.4%.

In rats given topical gentamicin (40 mg/mL), the SNR values were significantly lower at 3000 and 4000 Hz, but no significant difference was detected at 2000 Hz. In histopathological examination, it was seen that histopathological changes detected in organ of corti, spiral ganglion cells, and stria vascularis in the negative control group were similar to those detected in the study group.

Although there are studies suggesting that alcohol concentration in the solution used in our study wasn't high enough to lead to ototoxicity, failure to discuss acetone is a limitation of this study. Acetone has an ototoxic potential or carries risk to potentiate mercurochrome ototoxicity; however, there is no study on this topic. The investigation of the effect of acetone with additional experiments might have in-

creased the reliability of this study. Further studies using acetone-free mercurochrome solution or that may reveal potential ototoxic effects of acetone are needed. Also rats have been shown to respond to frequencies of up to 80,000 Hz^[20, 21]. Therefore, in this study, functional evaluation of the basal turn of the cochlea may be sub-optimal.

CONCLUSION

In our study, the auditory and histopathological data indicate that topical mercurochrome use leads to ototoxicity in rats with induced tympanic membrane perforation. In clinical practice, we recommend to avoid mercurochrome in the manner in which it may pass into the middle ear in the presence of perforation.

Ethics Committee Approval: Ethics committee approval was received for this study from the ethics committee of Ege University Animal Experiment (Date: 23.12.2011 No: 2011-189).

Informed Consent: N/A.

Peer-review: Externally peer-reviewed.

Author Contributions: Concept – S.K., M.E.C., G.C., A.D., S.İ., L.O., M.Z.Ö.; Design – S.K., M.E.C., G.C., A.D., S.İ., L.O., M.Z.Ö.; Supervision – S.K., M.E.C., G.C., A.D., S.İ., L.O., M.Z.Ö.; Resource – S.K., M.E.C., G.C., A.D., S.İ., L.O., M.Z.Ö.; Materials – S.K., M.E.C., G.C., A.D., S.İ., L.O., M.Z.Ö.; Data Collection and/or Processing – S.K., M.E.C., G.C., A.D., S.İ., L.O., M.Z.Ö.; Analysis and/or Interpretation – S.K., M.E.C., G.C., A.D., S.İ., L.O., M.Z.Ö.; Literature Search – S.K., M.E.C., G.C., A.D., S.İ., L.O., M.Z.Ö.; Writing – S.K., M.E.C.; Critical Reviews – A.D., L.O., M.Z.Ö.

Acknowledgements: Thanks to Hasan Cem Irkilata for supervising the manuscript.

Conflict of Interest: The authors have no conflict of interest to declare.

Financial Disclosure: The authors declared that this study has received no financial support.

REFERENCES

- Hannley MT, Denny JC 3rd, Holzer SS. Use of otological antibiotics in treating 3 common ear diseases. *Otolaryngol Head Neck Surg* 2000; 122: 934-40. [\[CrossRef\]](#)
- Munguia R, Daniel SJ. Otological antifungals and otomycosis: a review. *Int J Pediatr Otorhinolaryngol* 2008; 72: 453-9. [\[CrossRef\]](#)
- Wolf SE, Swaddle JP, Cristol DA, Buchser WJ. Methylmercury exposure reduces the auditory brainstem response of zebra finches (*Taeniopygia guttata*). *J Assoc Res Otolaryngol* 2017; 18: 569-79. [\[CrossRef\]](#)
- Roth JA, Salvi R. Ototoxicity of divalent metals. *Neurotox Res* 2016; 30: 268-82. [\[CrossRef\]](#)
- Liang GH, Järlebark L, Ulfendahl M, Moore EJ. Mercury (Hg²⁺) suppression of potassium currents of outer hair cells. *Neurotoxicol Teratol* 2003; 25: 349-59. [\[CrossRef\]](#)
- Huang CF, Hsu CJ, Liu SH, Lin-Shiau SY. Ototoxicity induced by cinnabar (a naturally occurring HgS) in mice through oxidative stress and down-regulated Na⁽⁺⁾/K⁽⁺⁾-ATPase activities. *Neurotoxicology* 2008; 29: 386-96. [\[CrossRef\]](#)
- Chander J, Maini S, Subrahmanyam S, Handa A. Otomycosis—a clinicomycological study and efficacy of mercurochrome in its treatment. *Mycopathologia* 1996; 135: 9-12. [\[CrossRef\]](#)
- Mishra GS, Mehta N, Pal M. Chronic bilateral otomycosis caused by *Aspergillus niger*. *Mycoses* 2004; 47: 82-4. [\[CrossRef\]](#)
- Haynes DS, Rutka J, Hawke M, Roland PS. Ototoxicity of topical drugs—an update. *Otolaryngol Clin North Am* 2007; 40: 669-83. [\[CrossRef\]](#)
- Rutka J. Topical aminoglycosides? No. The case against using these agents in chronic ear disease. *Ear Nose Throat J* 2003; 82: 9-12.
- Tisner J, Millán J, Rivas P, Adiego I, Castellote A, Valles H. Otomycosis and topical application of thimerosal: study of 152 cases. *Acta Otorrinolaringol Esp* 1995; 46: 85-9.
- Mgbor N, Gugnani HC. Otomycosis in Nigeria: treatment with mercurochrome. *Mycoses* 2001; 44: 395-7. [\[CrossRef\]](#)
- Ueda H, Nakata S, Hoshino M. Effects of effusion in the middle ear and perforation of the tympanic membrane on otoacoustic emissions in guinea pigs. *Hear Res* 1998; 122: 41-6. [\[CrossRef\]](#)
- LeBourgeois HW 3rd, Anand VK, McAuley JR, Dickman JD, Malphurs O Jr. Effect of tympanic perforations on the detection of distortion-product otoacoustic emissions. *Ear Nose Throat J* 2000; 79:610-2, 614-6, 618.
- Zhao F, Wada H, Koike T, Ohyama K, Kawase T, Stephens D. Transient evoked otoacoustic emissions in patients with middle ear disorders. *Int J Audiol* 2003; 42: 117-31. [\[CrossRef\]](#)
- Gültekin E, Yener M, Özdemir İ. The effect of topical Castellani solution on outer hair cell function of rats. *Laryngoscope* 2010; 120: 808-12. [\[CrossRef\]](#)
- Aktas S, Basoglu MS, Aslan H, Ilknur AE, Dundar R, Katilmis H, et al. Hearing loss effects of administering boric alcohol solution prepared with alcohol in various degrees on guinea pigs (an experimental study). *Int J Pediatr Otorhinolaryngol* 2013; 77: 1465-8. [\[CrossRef\]](#)
- Morizono T, Sikora MA. Ototoxicity of ethanol in the tympanic cleft in animals. *Acta Otolaryngol* 1981; 92: 33-40. [\[CrossRef\]](#)
- Ozturkcan S, Dundar R, Katilmis H, et al. The ototoxic effect of boric acid solutions applied into the middle ear of guinea pigs. *Eur Arch Otorhinolaryngol* 2009; 266: 663-7. [\[CrossRef\]](#)
- Kelly JB, Masterton B. Auditory sensitivity of the albino rat. *J Comp Physiol Psychol* 1977; 91: 930-6. [\[CrossRef\]](#)
- Zheng CM, Ito S, Minami S, Horikawa J, Murata K. Frequency thresholds of rat cochlear nerve fibers. *Jpn J Physiol* 1992; 42: 459-72. [\[CrossRef\]](#)